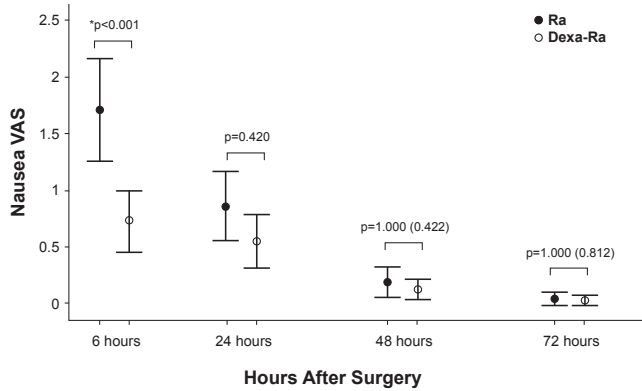




(76% vs 60%; $p=0.006$), compared with administration of Ra alone. Patients in the Dexa-Ra group also experienced less severe nausea during the first 6 hours (1.6 vs 2.6; $p<0.001$; Figure 1). However, there was no significant difference in the incidence of PONV or nausea between the treatment groups from 6 to 72 hours.

Figure 1. Postoperative Nausea Severity



Dexa-Ra=low-dose dexamethasone with ramosetron; R=ramosetron alone; VAS=visual analog scale.

Reproduced from Koh IJ et al. Preemptive Low-dose Dexamethasone Reduces Postoperative Emesis and Pain After TKA: A Randomized Controlled Study. *Clin Orthop Relat Res*. 2013;471:3010-3020. With permission from Springer.

Dexa-Ra was also associated with less pain (mean VAS pain score 2.4 vs 4.0; $p<0.001$), and opioid consumption (73.5 vs 128.3 μg ; $p<0.001$) from 6 to 24 hours, and reduced overall opioid consumption during the entire 72-hour period (406.2 vs 500.1 μg ; $p=0.004$).

There was no significant difference in wound complications (1.5% vs 2.2%; $p>0.1$) between the groups, and one patient in each group had periprosthetic joint infection (0.7% vs 0.7%; $p>0.1$).

Prof. Koh concluded that the use of dexamethasone in multimodal protocols offers a simple, effective, and inexpensive means of reducing pain and PONV following TKA, without apparent increased risk of wound complications or infection. He stressed, however, that more clinical trial data would be necessary to further evaluate the effect of dexamethasone on wound complications or infection in these patients.

Active Elbow Rotation Delays Healing Time in Radial Head Fractures

Written by Emma Hitt Nichols, PhD

Active elbow rotation within the first 2 weeks after radial head fracture resulted in delayed healing and increased pain compared with restricted elbow use. Nikolaos K. Paschos, MD, University of California, Davis, Davis, California, USA, presented data from a study that evaluated the effect of active elbow rotation in the treatment of radial head fractures.

A large amount of load is transmitted through the radial head during elbow movement, thus making the radial head an important structure in elbow joint stability. The purpose of this study was to determine the effect of introducing active elbow rotation early in the treatment of radial head fractures.

In the prospective, blinded trial, 300 patients with Mason type I or II radial head fractures were randomly assigned to receive 1 of 2 treatment protocols and followed for 2 years. In all patients, the affected limb was immobilized for the first 48 hours. In the first protocol, patients were then treated by mobilization of the affected limb via active flexion and extension of the elbow joint; active pronation and supination were not allowed until 15 days post injury. In the second protocol, patients were treated via active flexion and extension, as well as rotation, of the elbow joint. Follow-up was performed by a blinded orthopedic surgeon two times per week for the first 6 weeks, then once per week for the remaining 3 months. Radiographs were taken during Weeks 1, 4, 8, and 12 and then at the end of the first and second years.

Nonunion of the fracture occurred significantly more frequently in patients who were treated with elbow rotation ($n=14$) compared with patients who were not treated with active elbow rotation ($n=2$; $p<0.01$). In addition, patients who were treated with active elbow rotation demonstrated greater deficit in range of motion (10.3 vs 3.2; $p<0.01$) and pain as measured by the Visual Analogue Scale (1.7 vs 0.6; $p<0.05$) compared with patients who were not treated with elbow rotation. Furthermore, the mean time to fracture healing was significantly better in the patients who did not perform active elbow fracture (28.2 days) compared with those patients who did (36.1 days; $p<0.01$). The American Shoulder and Elbow Surgeons-Elbow score, and grip and pinch strength were similar among both groups.

Introducing active elbow rotation shortly after radial head fracture resulted in poorer outcomes. Dr. Paschos suggested that this is likely due to the additional instability caused by the forces transmitted during active elbow rotation, resulting in delayed healing and potential for fragment displacement. Therefore, he noted that active elbow rotation should be restricted for the first 2 weeks following radial head fracture.

Hyaluronic Acid Is No Better Than Placebo in Knee Osteoarthritis

Written by Nicola Parry

Walter van der Weegen, MSc, St. Anna Hospital, Geldrop, The Netherlands, presented results from a double-blind, randomized clinical trial demonstrating that injections of hyaluronic acid (HA) were no more effective than placebo in treating patients with knee osteoarthritis (KOA).

Whether the use of synthetic HA injections are helpful for KOA has been the subject of debate for decades. Numerous published reviews on the effectiveness of HA treatment in this patient population have been inconclusive [Rutjes AW et al. *Ann Intern Med* 2012; Arrich J et al. *CMAJ* 2005; Reichenbach S et al. *Arthritis Rheum* 2007; Divine JG et al. *Clin Orthop Relat Res* 2007; Bellamy N et al. *Cochrane Database Syst Rev* 2006].

However, data from patients at St. Anna Hospital have demonstrated potential efficacy of HA treatment in KOA. With this in mind, Prof. van der Weegen and colleagues conducted a randomized, double-blind, placebo-controlled trial to collect more information on the effectiveness and safety of HA injections in this patient population. The study aimed to determine whether HA injections would be more effective than placebo for knee pain and function in KOA.

Inclusion criteria included patients with a radiographic score of 1 to 3 based on the Kellgren and Lawrence grading scheme. Patients previously treated with HA were excluded.

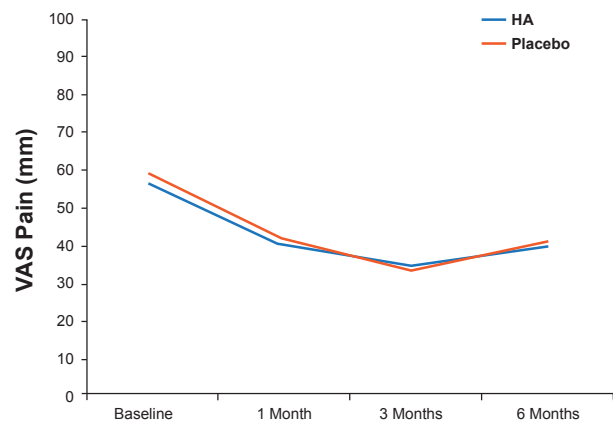
Patients (n=200) at two hospitals with mild to moderate KOA received either three intra-articular injections of HA (2 mL injections, 30 mg HA with a molecular weight of 2.2 M Dalton) or placebo at weekly intervals, with follow-up at 1, 3, and 6 months to assess visual analog scale (VAS) scores for pain, Western Ontario and McMaster Universities Arthritis (WOMAC) scores, knee range of motion, treatment satisfaction, and adverse events. Baseline details, including age, KOA severity, and pain scores were similar in both groups.

Although patients' pain scores improved significantly from baseline, there was no significant difference between the two groups (Figure 1). Additionally, there was no significant difference between groups at any of the follow-up time intervals in all other outcome measurements (VAS scores for pain, WOMAC scores, knee range of motion, and treatment satisfaction). No serious adverse events were reported in either of the treatment groups.

Similarly, although subgroup analyses on pretreatment duration of symptoms, pain severity, and radiological KOA severity were also performed, there were no significant differences between subgroups.

Although an earlier study using the same HA as used in this trial demonstrated clinical improvement from baseline [McDonald C et al. *J Clin Res* 2000], the results of this current study showed that three injections of HA were no more effective than placebo. Prof. Van der Weegen therefore concluded that HA treatment can not be recommended for patients with mild to moderate knee OA.

Figure 1. Visual Analog Scale Scores for Pain



Fermathron plus is the hyaluronic acid compound used in the study.
Reproduced with permission from WA. van der Weegen, MD.

Fewer Anterior Cruciate Ligament Reconstruction Failures With Autografts Versus Allografts

Written by Emma Hitt Nichols, PhD

Anterior cruciate ligament (ACL) reconstruction with hamstring autograft (AUTO) resulted in fewer reconstruction failures compared with tibialis posterior tendon allograft (ALLO) at 10 years. Craig R. Bottoni, MD, Honolulu, Hawaii, USA, presented data from a study that compared the long-term outcomes of autograft versus allograft ACL reconstruction.

Autografts are commonly used in ACL reconstruction, but allografts are becoming an increasingly popular alternative. However, the use of allografts has been associated with greater failure rates, particularly in young athletes, compared with autografts. Confounding variables include graft type, processing of the graft, and fixation method of the graft. The purpose of this study was to determine the long-term outcomes of primary ACL reconstruction using autograft or allograft.

In this prospective, randomized clinical trial, 99 patients (100 knees) with symptomatic ACL-deficient knee were randomly assigned to undergo ACL reconstruction with an AUTO or ALLO procedure. The allografts were from the same tissue bank and were aseptically processed and fresh frozen, and did not receive terminal irradiation. The method of graft fixation was identical in all cases, and patients participated in the same postoperative rehabilitation protocol, which was blinded to the physical therapists. Follow-up assessment was performed via telephone at a minimum of 10 years post surgery to determine functional and subjective status.