

Table 2. Outcomes of Patient Transfer to Paris on ECLS

Age, y	Diagnosis	Outcome
41	DCM	Day 6, Impella; emergency list for transplantation Day 23, died of septic shock
54	DCM	HeartWare; alive after 3 y
63	DCM, AMI	Day 4, Impella, ECLS weaning Day 20, died weaning Impella
20	DCM	IABP, heparin-induced thrombocytopenia, thrombosis in ECLS circuits, died
46	Massive AMI	Day 6, IABP Day 10, transplantation, alive
45	DCM	Day 4, IABP Day 10, HeartWare, alive
49	DCM	Day 6, Impella, emergency list for transplantation, alive
8	Cardiogenic shock	HeartWare, alive
61	DCM, AMI	Day 4, Impella, ECLS weaning Day 15, died weaning ECLS
57	DCM	IABP, emergency list for transplantation

AMI=acute myocardial infarction; DCM=dilated cardiomyopathy; ECLS=extracorporeal life support; IABP=intra-aortic balloon pump.

destination therapies. In this case series, venoarterial ECMO-assisted transatlantic transport on a commercial flight appeared to be safe without any adverse events during device implantation and transfer and allowed several patients to receive advanced durable treatments for heart failure. As a result, patients living in the Antilles-Guiana region have the option to be transported to France, where they can be listed for emergency heart transplantation or undergo placement of a ventricular assist device.

Catheter Ablation in AF

Written by Emma Hitt Nichols, PhD

The underlying mechanisms of atrial fibrillation (AF) and its initiation are not well understood, yet catheter ablation can effectively terminate AF in many patients. Ravi Kishore Amancharla, MD, Health City Cayman Islands, Grand Cayman, discussed the benefits of ablation for patients with AF.

There are 2 major competing theories about the mechanism of AF. The “spatially localized” theory suggests that AF is the result of automaticity or localized reentry, whereas the “spatially meandering” theory suggests that

AF is the result of multiple-wave reentry. Dr. Amancharla stated that initiation of AF is likely a result of both focal triggers and abnormal substrate.

Catheter ablation of AF focuses on likely focal triggers, and the method used depends on the location. A majority of foci are located within the pulmonary vein [Haissaguerre M et al. *N Engl J Med* 1998], as the muscular sleeve of atrial tissue can be found several centimeters into the adjoining region of the vein. By placing multiple catheters into the pulmonary veins, the location of the trigger can be isolated. However, the triggers may not consistently arise from the same location; therefore, the method changes to ablation of the entire segment of the pulmonary vein. Yet, the muscle sleeve can extend deeper into the atrium, so a large portion of the pulmonary vein is disconnected from the atrium, to lower the risk of recurrence due to better isolation of the pulmonary vein. Despite these improvements, the 5-year recurrence rate at a single center was about 30% following a single procedure (Figure 1). According to Dr. Amancharla, these data suggest that ablation works, but multiple procedures are required for sustained success. The inconsistent results of pulmonary vein isolation may be a result of variable anatomy, inaccurate delineation of the ostium and antrum, the inability to produce an enduring transmural lesion without gaps, and targeting the wrong mechanism. Incorporating newer imaging techniques can help limit these issues, as can the use of a cryoballoon, a circular ablation catheter, and contact force ablation catheters.

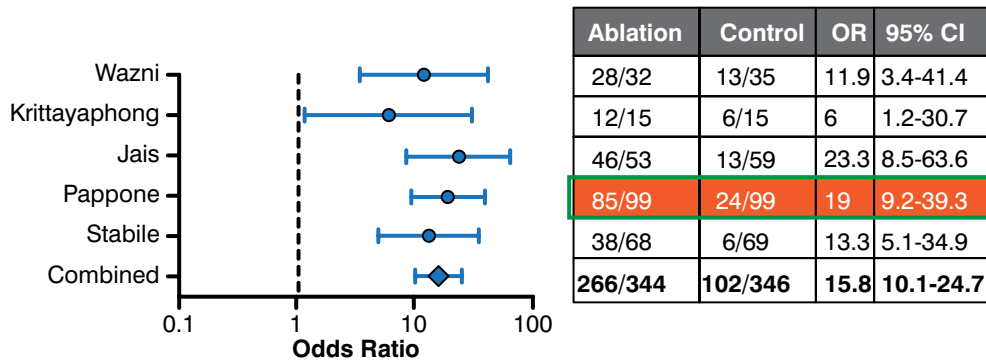
In some patients, other mechanisms beyond the pulmonary vein should be considered, particularly in patients who have persistent to permanent disease. The pulmonary vein plays a lesser role as a trigger for disease in persistent and permanent AF [Fisher JD et al. *Pacing and Clin Electrophysiol* 2006]. As a result, the ablation strategy should change. The atrial substrate must be identified via electrophysiologic mechanisms and structure.

For linear lesions, areas of the left atrium are identified to reduce the critical mass, which are required for multiple-wave reentry. Commonly used lines include the perimitral and roof lines [Cabrera JA et al. *Eur Heart J* 2006], which function to compartmentalize the atria into segments that reduce the risk of recurrence.

Targeting complex potentials, as indicated by complex fractionated atrial electrograms (CFEs), is typically used as an adjuvant strategy with pulmonary vein isolation or linear ablation. CFEs are composed of ≥ 2 deflections or a continuous deflection from baseline of a prolonged activation complex over a 10-second recording. However, Dr. Amancharla commented that the opinion of most



Figure 1. Ablation vs Medical Therapy in Atrial Fibrillation



Reproduced from Piccini JP et al. Pulmonary vein isolation for the maintenance of sinus rhythm in patients with atrial fibrillation: a meta-analysis of randomized, controlled trials. *Circ Arrhythm Electrophys.* 2009;2:626-633. With permission from Lippincott Williams and Wilkins/Wolters Kluwer Health.

electrophysiologists is that targeting only CFEs is no longer recommended.

Another method that can terminate persistent AF is alcohol ablation via the Marshall vein, which is a rudimentary structure that connects the proximal coronary sinus to the atrial appendage. However, the Marshall vein also supplies multiple ganglion plexi; therefore, Dr. Amancharla postulated that the mechanism of AF termination is blockade of the autonomic nervous system.

In conclusion, Dr. Amancharla stated that the lesson learned from this stepwise approach of ablation is that up to ~87% of patients experience AF termination with 3 hours of ablation. Importantly, the trigger is terminated slowly, and the exact trigger may not necessarily be known. However, despite the limitations of ablation, it is still favored over medical therapy in patients who have been failed by an antiarrhythmic agent, according to a systematic review (Figure 1) [Piccini JP et al. *Circ Arrhythm* 2009].

Patient Presenting With Nonpitting Edema Diagnosed With MTS

Written by Phil Vinall

May-Thurner syndrome (MTS), also known as Cockett syndrome or ileocaval compression syndrome, is a vascular anomaly first described in 1956 by R. May and J. Thurner. This syndrome frequently involves pain and significant swelling of the whole limb; however, not all patients present with symptoms. When they do, besides pain and swelling, symptoms may include left leg pain and edema, pulmonary embolism, deep vein thrombosis, varicose veins, and chronic ulcerations.

Ramona A. Lappot Guzmán, MD, Medicina Cardiovascular Asociada, Santo Domingo, Dominican Republic, described a case of a male patient aged 16 years without past medical history who was referred to her practice after 10 months of pain and severe progressive nonpitting edema of the left leg. On examination, the swelling presented distally from the left thigh to the ankle. There was tenderness to the palpation but normal pulses, reflexes, and strength.

Ultrasonography showed a huge amount of thrombi in the left superficial femoral vein and the anterior tibia vein that persisted even after aggressive warfarin therapy. Extensive workup for thrombophilia, malignancies, and autoimmune diseases yielded negative results. Computed tomography angiography of the pelvis revealed inadequate venous opacification at the level of the iliac veins but no thrombosis, masses, or anatomic defects. Simultaneous venography and arteriography revealed normal anatomy of the arteries but did show an extrinsic compression of the left common iliac vein at the entry of the vena cava that was caused by an overlying right common iliac artery. This led to a diagnosis of MTS.

Treatment consisted of placing a vena cava filter below the renal veins and a stent where the left common iliac vein was compressed. Good expansion, antero-grade flow, and a lumen opening of 95% of normal were achieved. The patient was discharged 3 days later without complications and with considerable edema reduction. There was good long-term recovery, although the patient remains on warfarin.

Once the condition has been identified (best by venography), traditional therapy is anticoagulation and, recently, endovascular procedures. MTS should be considered when dealing with left leg pain.