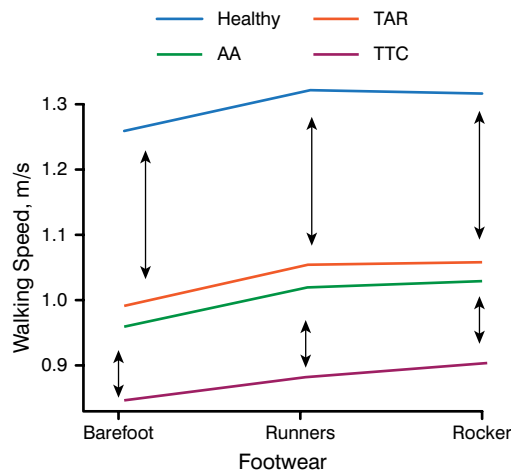
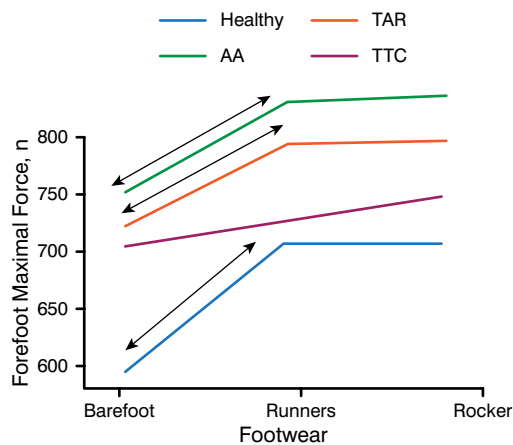


Figure 1. Walking Speed Results



AA, ankle arthrodesis; TAR, total ankle replacement; TTC, tibiototalcaneal. Reproduced with permission from A Frigg, MD.

Figure 2. Forefoot Maximal Force Results

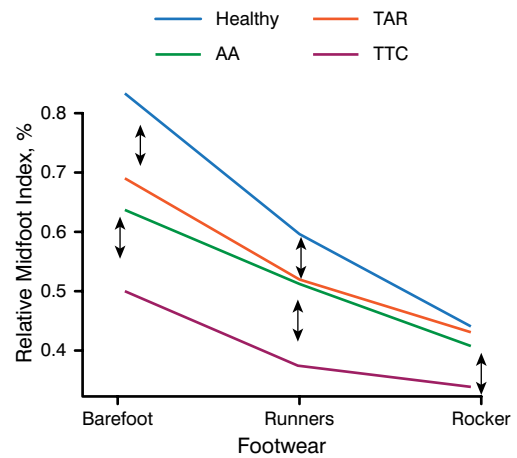


AA, ankle arthrodesis; TAR, total ankle replacement; TTC, tibiototalcaneal. Reproduced with permission from A Frigg, MD.

($P=.07$ to $.86$). There was no significant difference in forefoot MF between patients treated with TAR or AA in any of the conditions ($P=.7$ to $.9$). Patients treated with TTC ankle fusion had results that were inferior to those of both TAR and AA (Figure 2).

In patients who were barefoot, rMI was significantly smaller with the TAR and AA groups, relative to healthy controls ($P<.01$), but not significantly different between TAR and AA ($P=.35$). In running shoes, there was no difference between TAR and AA, but there was a significant

Figure 3. Relative Midfoot Index Results



AA, ankle arthrodesis; TAR, total ankle replacement; TTC, tibiototalcaneal. Reproduced with permission from A Frigg, MD.

difference compared with healthy controls ($P<.05$). In rocker-bottom shoes, there were no significant group differences ($P=.48$). TTC ankle fusion was associated with a significantly smaller rMI in all conditions compared with the other groups ($P<.001$; Figure 3).

This study found no measurable difference in running shoes or rocker-bottom shoes between patients treated with TAR and AA. In addition, an increased forefoot MF that might be a trigger for adjacent osteoarthritis was not found in patients treated with AA compared with those treated with TAR. Patients treated with TTC ankle fusion have an inferior functional outcome.

Prof. Frigg questioned whether there was any benefit for TAR over AA considering TAR's high rates of failure [Henricson A et al. *Acta Orthop*. 2011] and revision [SooHoo NF et al. *J Bone Joint Surg Am*. 2007] compared with AA.

Early and Delayed Weight-Bearing Outcomes the Same Following Microfracture

Written by Phil Vinall

Injury to the articular cartilage and subchondral bone of the talar dome rarely heals without treatment, and nonsurgical treatment is successful only 45% of the time [Verhagen RA et al. *Foot Ankle Clin*. 2003]. Neither approach is recommended for osteochondral lesions of the talus (OLTs), which are best treated by arthroscopic bone marrow stimulation with microfracture surgery,



particularly for symptomatic OLTs < 15 mm in diameter. This procedure is technically simple and minimally invasive with low complication rates and postoperative pain [Ferkel RD et al. *Am J Sports Med.* 2008].

However, the quality and volume of repair tissue can be affected by postoperative loading, with excessive loads causing destruction of repaired tissue. For this reason, early non-weight bearing range-of-motion exercises for a minimum of 6 to 8 weeks, followed by progression to full weight bearing by 3 months, are widely recommended [Ferkel RD et al. *Am J Sports Med.* 2008]. Although a few investigators have reported successful outcomes after early weight bearing in patients treated with microfracture for chondral knee and ankle injuries with lesions < 15 mm in diameter [Li S et al. *Chin Med J.* 2014; Lee DH et al. *Am J Sports Med.* 2012], early and delayed (or non-weight bearing for 6 weeks) postoperative treatments after microfracture have not been compared in a randomized controlled trial.

Keun-Bae Lee, MD, PhD, Chonnam National University Hospital, Gwangju, Korea, reported that delayed and early weight-bearing postoperative regimens are equally beneficial for patients treated by microfracture for small to midsized OLTs.

Of 99 patients presenting with OLTs, 41 were randomized to delayed weight bearing and 40 to early weight bearing. For patients in the delayed weight-bearing arm, a posterior splint was applied during the first week. Active ankle range-of-motion and strength exercises were started in the second week. Non-weight bearing was maintained for 6 weeks. After 8 weeks, the posterior splint was removed. Patients in the early weight-bearing arm also received a posterior splint during the first week. Early in week 2, partial weight bearing in a walking boot was allowed, followed by early full weight bearing as tolerated. After 8 weeks, the walking boot was removed.

There were no significant demographic differences between the 2 arms. The mean age was 36 years; the majority were men; and the mean lesion size was 1.0 cm². There were no differences in American Orthopaedic Foot & Ankle Society scores preoperatively or during follow-up out to 24 months between the arms. There were also no differences in visual analogue scale or ankle activity score during postoperative follow-up out to 24 months.

No significant correlations were found between final American Orthopaedic Foot & Ankle Society scores based on sex, age, body mass index, duration of symptoms, or lesion size. Similar outcomes for delayed and early weight-bearing postoperative treatments suggest that either approach can be recommended for patients treated by microfracture for small to midsized OLTs.

MAST Is Safe and Effective in Treatment of Chondral Defects of Foot and Ankle

Written by Phil Vinall

According to a study reported by Martinus Richter, MD, Hospital Rummelsberg, Schwarzenbruck, Germany, matrix-associated stem cell transplantation (MAST) is a safe and effective method for the treatment of chondral defects of the foot and ankle. Its main advantage is that it requires only a single procedure.

MAST is a modified version of matrix-induced autologous chondrocyte implantation (ACI) that allows for implantation of a potentially higher concentration of stem cells [Richter M, Zech S. *Foot Ankle Surg.* 2013]. For this open surgical procedure, stem cell-rich blood (about 3% stem cells) is harvested from pelvic bone marrow and centrifuged at 1500 revolutions per minute to double the concentration of stem cells. The resulting cells are implanted via microfracturing or bone transplantation in the case of a defect that is deeper than 5 mm, through a collagen matrix impregnated with the stem cell and fibrin glue. Motion is permitted 3 days postsurgery. Postoperative treatment includes 15 kg of partial weight bearing for 6 weeks.

In this more recent prospective study, surgeons determined 75 consecutive patients (78 defects) to be eligible for MAST based on initial arthroscopy. All procedures took place between April 2009 and September 2011. Defect size, procedural time, and Visual Analogue Scale Foot and Ankle (VAS-FA) score were recorded. Patients were followed for 2 years. There was no control group.

Patients (mean age, 34 years; range, 16 to 64; 72% men) had a mean baseline VAS-FA score of 50.2 out of 100 (range, 24.3 to 68.4). Medial and lateral talar shoulders were the most common defect sites (28 patients each), followed by defects of the metatarsophalangeal joint 1 head (10 patients). Of the remaining 9 patients, 3 had defects of the medial and lateral shoulders; 3 had defects of the tibia; and 3 had defects of the calcaneus. The mean defect size was 1.1 cm² (range, 0.2 to 6); mean procedural time was 15.4 minutes (range, 5 to 38). Autologous bone graft was used in 3 cases. More than 300 additional procedures were performed at the time of MAST. All patients returned to work after an average of 6 weeks. At 24 months, mean VAS-FA scores were significantly ($P = .01$) increased (mean, 94.5; range, 73.4 to 100), and no complications were reported.

The results of this study indicate that MAST is safe and associated with good outcomes in patients with chondral defects of the ankle or foot. An important advantage over