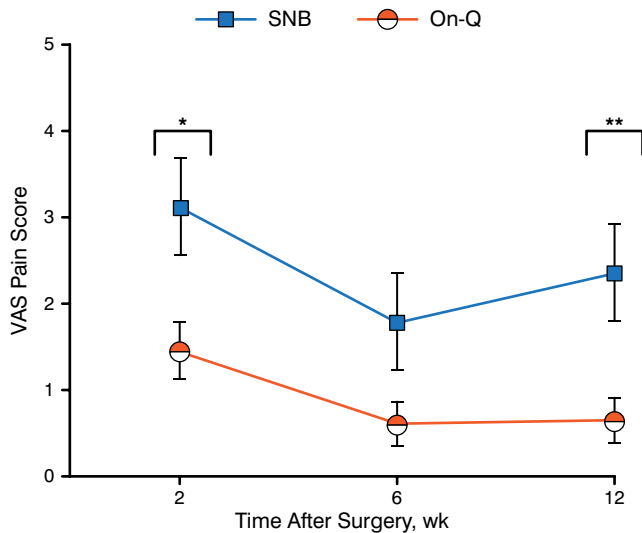




Figure 3. Visual Analog Scale Pain Levels at 2, 6, and 12 Weeks



SNB, sciatic nerve block as a single injection; VAS, visual analog scale.
^{*} $P=.014$. ^{**} $P=.004$.
 Reproduced with permission from NC Tejwani, MD.

the On-Q group discontinued treatment early (most at the 24-hour mark); all discontinuations were accidental or the result of either equipment malfunction or miscommunication on the part of the patient. There were no differences in side effects from narcotics or in infections or neurologic symptoms.

Continuous infusion of peripheral nerve anesthesia postoperatively is a safe and effective way to minimize rebound pain, reduce oral pain medications, and improve pain scores.

No Significant Differences Between Syndesmotic Fixation and No Fixation in Supination-External Rotation Ankle Fractures

Written by Wayne Kuznar

There is no significant difference in functional outcome or radiologic findings between syndesmotic transfixation and no fixation in patients with supination-external rotation IV ankle fracture after midterm follow-up. Tero Kortekangas, MD, Oulu University Hospital, Oulu, Finland, presented the results of a prospective randomized study [NCT01234493] comparing the 2 approaches in patients with intraoperatively confirmed syndesmosis disruption.

In the study, 140 patients with Lauge-Hansen single-injection IV (Weber B) ankle fractures were enrolled and tested for syndesmotic injury via the 7.5-Nm standardized external rotation stress test for both ankles [Pakarinen HJ et al. *Foot Ankle Int.* 2011]. A positive result was defined as a >2-mm side-to-side difference in the tibiotalar clear space or tibiofibular clear space on mortise radiographs. The mean side-to-side difference in tibiotalar clear space was 3.0 mm in both groups. The mean side-to-side difference in tibiofibular clear space was 3.5 mm in the group assigned to syndesmotic screw fixation and 3.2 mm in that assigned to no fixation. No syndesmotic injury was detected in 116 patients; the other 24 patients with a positive result were randomized to transfixation with 3.5-mm cortical screws (n=13) or no syndesmotic fixation (n=11).

At 1 year, there was no significant difference between the 2 groups with respect to the Olerud-Molander Ankle Score ($P=.50$), the 100-mm visual analog scale measuring ankle pain ($P=.38$) and function ($P=.37$), or the RAND 36-Item Health Survey measuring pain ($P=.32$) and function ($P=.23$) [Pakarinen HJ et al. *Foot Ankle Int.* 2011].

The mean follow-up time for the study was 4.8 years in both groups. No patient was lost to follow-up. At the early stage, good functional results remained. Within the syndesmotic transfixation group, improvements in all functional parameters and pain measurements were insignificant, whereas the group assigned to no fixation showed improvements in the Olerud-Molander Ankle Score (from 84 to 93) and visual analog scale pain (from 11 to 4) between year 1 and year 4, although there was no significant difference between groups in scores at year 4.

Ankle joint congruity and osteoarthritis (OA) were assessed via mortise and lateral projection plain weight-bearing radiographs and 3-T magnetic resonance imaging (MRI) scans. Ankle mortise congruity remained unchanged between short-term (12 weeks) and 4-year follow-up in both groups. Unfixed syndesmosis did not lead to an increased incidence of OA, said Prof Kortekangas.

Kellgren-Lawrence classification of OA was not significantly different between the groups, with the majority being grade 2 (definite osteophytes, narrowing of joint space) in both groups (92%, syndesmotic transfixation; 78%, no transfixation). MRI findings at the latest follow-up showed no significant difference between the groups in the height of the talocrural joint cartilage (anterior, $P=.16$; posterior, $P=.46$) and the height of the posterior facet cartilage ($P=.18$). MRI demonstrated joint cartilage defects in 67% in the syndesmotic transfixation group and 40% in the no fixation group ($P=.39$).