

Data analysis from multiple large trials shows that potential mechanisms of ST after DES implantation include delayed healing (failure of new neointimal formation and smooth muscle cell replication, poor endothelialization) and clopidogrel-related issues (premature discontinuation, inadequate platelet inhibition). In a Kaplan-Meier analysis, Roy et al. [*Eur Heart J* 2008] demonstrated significantly longer ST-free survival in patients with IVUS-guided stents versus no IVUS ($p=0.013$). A HORIZONS substudy [Choi SY et al. *Circ Cardiovasc Interv* 2011] reported that minimum lumen cross-sectional area (CSA), significant tissue protrusion, significant stent edge dissection, and significant residual stenosis but not acute malapposition were associated with early ST. However, Cook et al. [*Eur Heart J* 2012] found that the presence of CSA, assessed by IVUS 8 months after DES implantation, was associated with a higher rate of MI and very late ST during long-term follow-up.

The underlying mechanisms of late ST after DES implantation include abnormal or delayed healing, inadequate endothelial cell coverage on struts, and positive remodeling consistent with underlying vascular toxicity. IVUS may help us understand the mechanisms of late ST and reduce the incidence of ST.

Coronary Angioscopic Evaluation of Drug-Eluting Stents

Masaki Awata, MD, Osaka University Graduate School of Medicine, Osaka, Japan, discussed the results of his angioscopic studies of neointimal coverage (NIC) following drug-eluting stent (DES) implantation. NIC is graded from 0 to 3 as follows: 0=struts exposed similarly to time of implantation; 1=struts covered but not embedded by neointima; 2=struts embedded by neointima but are visible; 3=struts fully covered by neointima. Patients with grade 0/1 coverage have the potential for incomplete re-endothelialization.

Angioscopy of Bare Metal and Drug-Eluting Stents

Angioscopic evaluation at 3 to 6 months after stenting found complete NIC (Grade 2/3) in 2 of 15 patients implanted with the Cypher sirolimus-eluting stent, while all 22 patients with a bare-metal stent (BMS) had complete coverage [Kotani J et al. *J Am Coll Cardiol* 2006]. In another study [*Circulation* 2007], Dr. Awata and colleagues used serial angioscopy to evaluate NIC up to 2 years after BMS and DES implantation. He found that patients with the Cypher stent had Grade 1 coverage, 1 to 2 years after

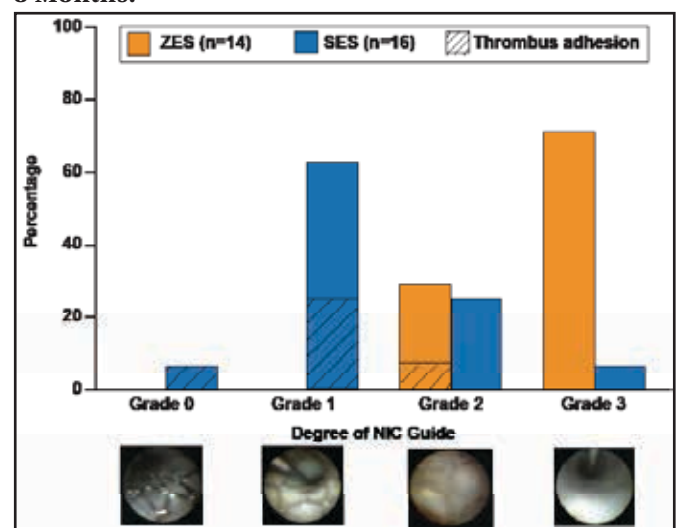
implantation; after 4 years, 60% of patients still had grade 1 coverage. Widely exposed struts were reported in 10% of patients 1 year after Cypher implantation. Yellow plaques were detected at 2 years after implantation.

In a study comparing the Cypher versus Taxus paclitaxel-eluting stent, patients with the Taxus stent experienced significantly better NIC at 8 months than those with the Cypher stent ($p<0.002$) [Awata M et al. *JACC Cardiovasc Interv* 2009]. A comparison of the Cypher sirolimus-eluting stent and the Endeavor zotarolimus-eluting stent 8 months after implantation demonstrated significantly greater NIC with the Endeavor stent ($p=0.0004$).

The new Nobori DES is coated abluminally with a biodegradable polymer and Biolimus A9, which is 10-fold more lipophilic than sirolimus. Comparison of heterogeneity of NIC grades at 8 months showed greater homogeneity with the Nobori stent versus the Cypher stent ($p=0.045$). NIC was not significantly better with the Nobori versus the Cypher at 8 months.

The new Xience V everolimus-eluting stent (0.0032") is much thinner than the Cypher (0.0055") and the Nobori (0.0053") stents. NIC coverage is significantly better with the Xience V versus the Cypher stent at 8 months after implantation ($p=0.001$; Figure 1) [Awata M et al. *J Am Coll Cardiol* 2008].

Figure 1. Comparison of Dominant NIC Grade at 8 Months.



NIC=neointimal coverage; SES=sirolimus-eluting stent; ZES=zotarolimus-eluting stent. Reproduced with permission from the American College of Cardiology. Awata M et al. Angioscopic Comparison of Neointimal Coverage Between Zotarolimus- and Sirolimus-Eluting Stents. *J Am Coll Cardiol*, August 26, 2008;52:789-790.

Dr. Awata concluded that the new technologies of the Nobori and Xience V stents should be adopted in next generation DES, including the drug and polymer-free luminal surface of the Nobori and the thinner strut of the Xience V.