

The Role and Importance of Plaque Modification Devices in Coronary Angioplasty

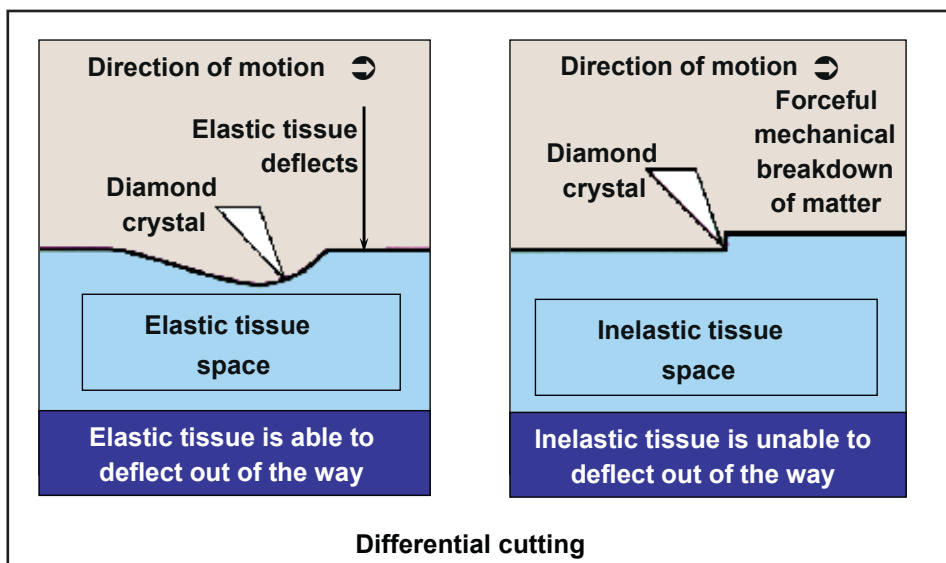
Written by Phil Vinall

Calcified coronary lesions may be associated with stent underexpansion, malapposition, and high rates of restenosis. Aggressive plaque modification (PM) before stenting can reduce the risk of restenosis [Vaquerizon B et al. *J Interv Cardiol* 2010]. Although data indicate that PM does not have a direct influence on target lesion restenosis, it improves stent expansion and makes otherwise impossible cases possible. José F. Díaz, MD, Juan Ramon Jimenez University Hospital, Huelva, Spain, provided an overview of the need for devices that are currently available to pretreat complex lesions with PM.

There are several mechanical approaches that are available for PM. Some have been developed to ablate atheromatous plaque during percutaneous coronary interventions (PCIs), including the rotablator, cutting balloon, and a scoring device, which is similar to the cutting balloon.

Rotational atherectomy is achieved using the diamond-headed rotablator, which employs differential cutting to remove inelastic tissue. Elastic tissue (healthy) is able to deflect out of the way of the rotablator and remains (Figure 1). The rotablator is best employed at medium rotational speeds (150,000 rpm) to polish the inside of the artery. This reduces platelet aggregation. This device should not be used in vessels with left ventricular dysfunction, vessels with extreme tortuosity, or saphenous vein grafts; where there is evidence of thrombus; for dissection; or in vessels with chronic total coronary occlusions. The rotablator has also not been proven to offer any advantages when used as a debulking device, at least regarding target vessel revascularization (TVR) or restenosis. However, it may be useful in situations in which there are heavily calcified lesions or the balloon is unable to cross/dilate the lesion.

Figure 1. Rotablator Principle of Operation.

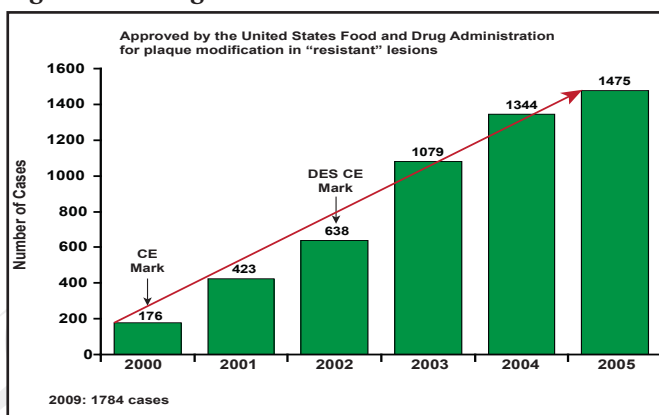


Reproduced with permission from J. Diaz, MD.

The cutting balloon consists of a noncompliant balloon with 3 to 4 cutting microtomes (a sectioning instrument that allows for the cutting of extremely thin slices) that are mounted on

its surface, allowing for controlled cutting of the intima. Like the rotablator, the use of the cutting balloon is increasing in Spain (Figure 2). Like the rotablator, balloon cutting offers no clear advantages regarding rates of restenosis and TVR, but its use does result in less dissection, bail-out stenting, balloon slippage, and plaque shifting. It may be particularly useful for small vessels, bifurcated vessels, ostial lesions, and in-stent restenosis. The major drawback is deliverability.

Figure 2. Cutting Balloon.



Reproduced with permission from J. Diaz, MD.

The third device, the scoring balloon, consists of 3 nitinol spiral “scoring” wires with nitinol-enhanced active deflation. It has a low crossing profile (2.7F) and is compatible with a 6F catheter or 5F sheath. It offers the advantages of being a nonslip device (avoids “geographic miss”), fewer dissections, fewer “snowplow effects” (pushing atherothrombotic material into a side branch or downstream), good deliverability, and having better stent expansion/apposition. One study has shown that pretreatment with the scoring balloon enhanced stent expansion and minimized the difference between predicted and achieved stent dimensions [De Ribamer Costa, Jr J et al. *Am J Cardiol* 2007]. In another study that was conducted in Israel (Israeli Registry), PM was performed with the scoring balloon prior to stent implantation in 745 patients. Procedural and clinical success rates were greater than 96%, device slippage occurred in only 1.2% of lesions, and there were no scoring balloon-related perforations.

Although early studies show the PM has little impact on the rate of restenosis, target lesion restenosis, or death rates and may increase procedural myocardial infarction and major cardiac adverse events [Bittl J et al. *J Am Coll Cardiol* 2004], Prof. Diaz believes PM may be important when dealing with selected acute cases. Specifically, it may help to decrease plaque volume and shifting, alter calcification, increase lesion compliance, facilitate stent delivery, and minimize vessel trauma.

Hybrid LIMA to LAD for Survival

Written by Phil Vinall

Hybrid coronary revascularization (HCR) is the planned use of a combination of minimally invasive surgical techniques for left internal mammary artery (LIMA) to left anterior descending (LAD) artery bypass grafting and the use of percutaneous coronary intervention (PCI) for revascularization of other territories that is performed during the same procedure. This hybrid approach for treating multivessel coronary artery disease (CAD) may offer the best of both worlds and is an alternative to coronary artery bypass grafting (CABG) through sternotomy alone or multivessel PCI. Ihab Attia, MD, FSCAI, Ain Shams University, Cairo, Egypt, discussed the pros and cons of this approach, pointing out the need for hybrid operating suites with surgical and fluoroscopic capabilities to support the performance of this procedure.

The LIMA is the optimal conduit for the LAD, in that it provides durable patency and is associated with survival advantages, while stenting the circumflex artery and right coronary artery with drug-eluting stents (DES) is also associated with excellent clinical outcomes. When combined with robotically enhanced minimally invasive surgery, this approach may be better tolerated than traditional CABG that is performed with a sternotomy. In addition, a hybrid strategy has the potential to offer optimal revascularization while providing patients with a truly minimally invasive approach that is potentially accompanied by reduced surgical trauma and reduced morbidity. Robotic LIMA is associated with less postthoracotomy syndrome and quicker recovery than minimally invasive direct coronary artery bypass (CAB).

Hybrid surgery may be best targeted to patients who are at high risk for sternotomy (elderly or frail patients and those with comorbidities), younger patients who may need other surgery in the future, those with complex LAD disease, and patients with left main disease when the circumflex is small and could be stented after a LIMA graft has been placed. Prof. Attia believes that the LAD should not be stented when there is ostial, bifurcation, or diffuse disease or if chronic occlusions are present because of the higher risk that is associated with stenting and better outcomes that are expected with CABG.

Aggressive continuous antiplatelet therapy is necessary after PCI and can be implemented if surgery is performed first. PCI of high-risk lesions may also be safer with a patent LIMA-LAD graft in place. The disadvantage of performing surgery first is that the fallback option of conventional