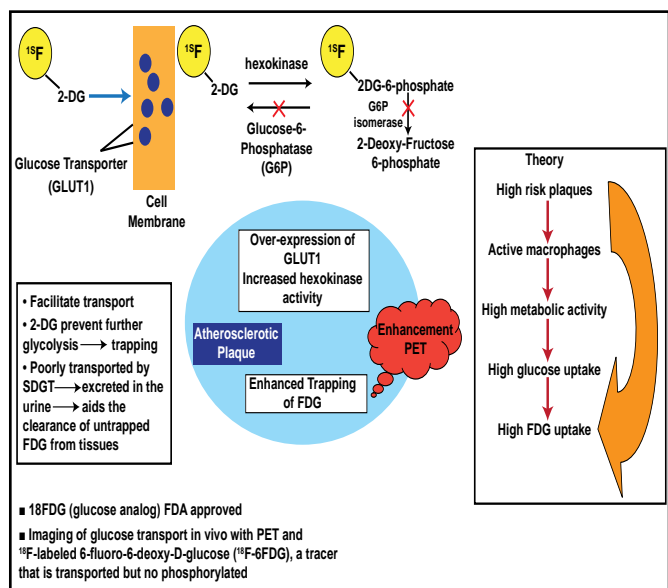


Studies have shown that FDG-PET is a useful tool for detecting molecular markers of inflammation and plaque vulnerability, which may have implications for stroke prevention and carotid atherosclerotic intervention assessment (Figure 1) [Tawakol A et al. *J Am Coll Cardiol* 2006; Graebe M et al. *Eur J Vasc Endovasc Surg* 2009]. Strong correlations have been found with FDG-PET uptake in carotid plaques and gene expression of the macrophage-specific marker CD68 (p=0.02). Weaker correlations have been found with cathepsin K, matrix metalloproteinase 9, and interleukin 18 gene expression.

The use of statins in atherosclerosis is not uncommon. In addition to the FDG-PET gene expression correlation, this technique, coupled with MRI, may be useful in monitoring anti-inflammatory effects of statins over time [Fayad ZA et al. *J Am Coll Cardiol* 2005; Tahara N et al. *J Am Coll Cardiol* 2006]. Using MRI and FDG-PET as evaluation tools, Dr. Fayad is currently assessing the efficacy of a drug on atherosclerotic plaque in an ongoing multicenter Phase II trial, the results of which are still pending.

In December 2009, the merging of imaging techniques was realized. The first whole-body multimodality scanner was introduced at the Mt. Sinai Medical School of Medicine. This technology allows CT, PET, and MRI to occur in the same setting. Although the cost of such technology may be an issue at the moment, Dr. Fayad explained that the benefit is significant, and as with many new technologies, the cost often decreases over time, especially once it enters mainstream clinical medicine.

Figure 1. PET/CT Detection of Plaque.



The Future of Intervention: Where Are We Now and Where Are We Going?

Interventional strategies have evolved over the past decade, and determining an optimal approach depends on many factors. Samin Sharma, MD, FACC, Mt. Sinai Medical Center, New York, NY, discussed the latest developments in cardiac intervention.

Left ventricular assist device (LVAD) support may be indicated for high-risk percutaneous coronary intervention (PCI) cases in the presence of severe left ventricular (LV) dysfunction (ejection fraction [EF] <30%), complex lesions in which transient closure may be catastrophic, large myocardial infarction (MI) with hemodynamic instability, or cardiogenic shock. The ongoing PROTECT II trial is evaluating the Impella Recover 2.5 system compared with a traditional intra-aorta balloon pump (IABP) during high-risk elective PCI procedures. A total of 654 elderly patients with triple vessel disease (mean age 69 years and mean EF 26.1±6%) will be randomized as part of this prospective, multicenter trial. The Impella system is a miniaturized LVAD system that is placed percutaneously via the femoral artery and actively unloads the ventricle, providing up to 2.5 L/min of flow with support up to 5 days. This device decreases myocardial O₂ demand and thus augments coronary and end-organ perfusion. The primary outcome is the composite rate of intraprocedural and postprocedural major events, including death, MI, stroke, transient ischemic attack, target vessel revascularization, coronary artery bypass grafting (CABG), acute renal failure, and severe hypotension [Sharma S. TCT 2009]. Secondary outcomes include maximum cardiac power output decrease from baseline and the rate of in-hospital major cardiac events (MACE) for Impella compared with IABP. Thus far, the rate of successful implantation for the Impella system is 100%, with 80% freedom from 1-year MACE for the first 20 consecutive elderly patients. Of these 20 patients, 40% required rotational atherectomy (n=8). Further results for the PROTECT II trial are pending.

The Coronary Sinus Reducer Stent, a percutaneous implantable device that is designed to narrow the coronary sinus and elevate coronary sinus pressure, may be a future option for patients with refractory angina who are not good candidates for conventional revascularization procedures. The first-in-man study of 15 patients showed that the Coronary Sinus Reducer Stent is safe and feasible for the treatment of refractory angina when conventional revascularization

is not an option [Banai S et al. *J Am Coll Cardiol* 2007]. Larger studies are required to further establish these findings.

Drug-eluting stents (DES) have also evolved, and we are now seeing many studies that are comparing first- and second-generation DES. Stone and colleagues are comparing everolimus-eluting (EES) with paclitaxel-eluting stents (PES) in the ongoing SPIRIT IV trial [Stone G. TCT 2009]. In this study, 3690 patients with a maximum of 3 lesions in 3 separate coronary arteries were randomized (2 to 1) to receive either EES or PES, after which they received aspirin ≥ 80 mg for 5 years and clopidogrel ≥ 75 mg for at least 12 months (when not at risk for bleeding). Clinical follow-up occurred at 1, 6, and 9 months and annually for 1 to 5 years.

The primary endpoint was target lesion failure (TLF), defined as the composite of cardiac death, target vessel MI, or ischemia-driven target lesion revascularization. There was a significant reduction in TLF that was associated with the EES compared with the PES (38% RRR; $p < 0.0001$) at 1 year (Figure 1). Additionally, there was an 80% hazard reduction (95% CI, 27% to 94%; $p = 0.002$) in stent thrombosis in the EES group compared with the PES group. There was no significant difference between the two groups for TLF in patients with diabetes [Stone G. TCT 2009]. Five-year outcomes are pending.

Bioabsorbable stent technology is also at the forefront of interventional cardiology. Preliminary findings from the ABSORB study showed that at 2 years postimplantation, vasomotion (ie, normal vasodilation and vasoconstriction) had been restored at the stented site and adjacent coronary artery and restenosis had been prevented in patients who received bioabsorbable EES. Of the 30 patients who were included in this pilot study, there was one non-Q wave MI but no cardiac death, ischemia-driven target lesion revascularization, or stent thrombosis that was recorded [Serruys PW et al. *Lancet* 2009]. The next arm of this study is underway and includes 80 patients.

Thrombus aspiration is another effective interventional technique. In the Thrombus Aspiration during Percutaneous Coronary Intervention in Acute Myocardial Infarction Study (TAPAS), investigating 1071 patients with possible ST-segment elevation MI, Svilaas and colleagues found that thrombus aspiration during PCI resulted in better reperfusion and clinical outcomes than conventional PCI. The thrombus aspiration group showed complete resolution of ST-segment elevation in 56.6% of patients and a myocardial blush grade of 0 to 1 in 17.1% of patients compared with 44.2% and 26.3% in the

conventional PCI group, respectively ($p < 0.001$ for both) [Svilaas T et al. *N Engl J Med* 2008].

There are many new innovations in the area of interventional cardiology. Advancements are being made with the development of new technologies and approaches. It is important to remain visionary and continue in the pursuit of optimal therapies. Over the next decade, we will see the development of new areas of interventional therapy with a focus on safety and simplicity, concluded Dr. Sharma.

Figure 1. SPIRIT IV: One-Year Clinical Results.

