

Surveillance for CRC in Patients With IBD

Written by Emma Hitt Nichols, PhD

Patients with inflammatory bowel disease (IBD) are associated with higher rates of colorectal cancer (CRC) as compared with patients without IBD [Wang YR et al. *Am J Gastroenterol.* 2013]. As a result, patients with IBD should undergo CRC surveillance. A recent study demonstrated that patients with ulcerative colitis (OR, 3.05; 95% CI, 2.44 to 3.81) or Crohn disease (OR, 3.07; 95% CI, 2.23 to 4.21) were at the greatest risk of having missed CRC when compared with patients without IBD [Wang YR et al. *Am J Gastroenterol.* 2013]. A greater proportion of stage III/IV CRC was missed in patients with Crohn disease vs patients with ulcerative colitis or without IBD.

Tonya Kaltenbach, MD, MS, Veterans Affairs Palo Alto Health Care System, Palo Alto, California, USA, showed that these data highlight the importance of successful surveillance for CRC in patients with IBD. Successful surveillance is dependent on recognition of dysplasia, adequacy of sampling, potential interfering anatomy, endoscopic resectability, and patient compliance with surveillance.

A 2004 study of >2000 colonoscopies demonstrated that most dysplastic lesions are endoscopically visible. Subsequently, the 2015 SCENIC international consensus statement on the surveillance and management of dysplasia in IBD recommended that surveillance for CRC be performed with high-definition chromoendoscopy with targeted biopsy [Laine L et al. *Gastrointest Endosc.* 2015].

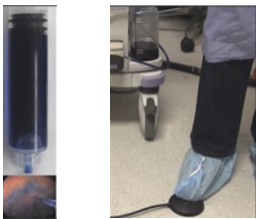
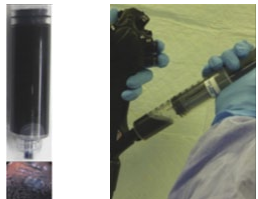
In addition, the consensus statement recommended against electronic-based image-enhanced endoscopy. This statement was based on data from 8 studies of >700 patients with IBD demonstrating that chromoendoscopy was favored over white-light standard-definition endoscopy for the detection of dysplasia and adenomas. In this study, the incremental yield of dysplasia using chromoendoscopy was 6% (95% CI, 2.8% to 9.2%).

Pan- vs targeted chromoendoscopy is used for different purposes (Table 1) [Laine L et al. *Gastrointest Endosc.* 2015]. In panchromoendoscopy, white light is used to visualize diluted indigo carmine image-enhanced endoscopy to detect lesions. For diagnosis, targeted chromoendoscopy uses a more concentrated solution of indigo carmine to visualize the surface pattern of the lesion. Abnormalities such as slightly elevated lesions, focal friability, obscure vascular patterns, uneven discoloration, villous mucosa, and irregular nodularity indicate a need for tissue sampling [Soetikno R et al. *Gastrointest Clin N Am.* 2014].

To allow visualization of dysplastic abnormalities, it is important that any active IBD is treated prior to surveillance. In addition, the bowel must be properly prepared since remaining wash residue can obstruct the view. The presence of pseudopolyps or strictures can also complicate detection.

In conclusion, Dr Kaltenbach pointed out that in patients with IBD, the traditional method of obtaining random tissue samples to detect dysplasia is no longer sufficient and, instead, vital stain chromoendoscopy with targeted tissue sampling should be used.

Table 1. Use of Chromoendoscopy Techniques

Purpose	Technique	Method	Dilution*	Color
Lesion detection	Pan chromoendoscopy	Water jet channel using auxillary foot pump or biopsy channel using spray catheter	Indigo carmine (0.8%, 5ml ampule): 2 ampules + 250ml water (0.03%) Methylene blue (1%, 10ml ampule): 1 ampule + 240ml water (0.04%)	
Lesion characterization and delineation of borders	Targeted chromoendoscopy	Syringe spray through biopsy channel	Indigo carmine (0.8%, 5ml ampule): 1 ampule + 25ml water (0.13%) Methylene blue (1%, 10ml ampule): 1 ampule + 40ml water (0.2%)	

*Various dilutions ranging from 0.03%-0.2% of indigo carmine and methylene blue have been reported for panchromoendoscopy.

Reprinted from *Gastrointest Endosc*, Vol 81, Laine L et al, SCENIC international consensus statement on surveillance and management of dysplasia in inflammatory bowel disease, Pages No. 489-501, Copyright (2015), with permission from American Society for Gastrointestinal Endoscopy and American Gastroenterological Association.