



p=0.05). These were exploratory end points and demonstrate that goserelin is at least safe to administer. The reason for improved DFS and OS in the goserelin arm in patients with hormone-receptor negative breast cancer is not well understood.

Grade 3/4 endocrine toxicity occurred more frequently in the goserelin arm compared with the arm that received chemotherapy alone (p=0.0006). The most common reported adverse events related to goserelin therapy included hot flashes, mood changes, vaginal dryness, and headache. In addition, one grade 4 thromboembolic event occurred.

In conclusion, Dr. Moore stated that goserelin should be considered in premenopausal women with hormone-receptor negative breast cancer receiving neoadjuvant or adjuvant chemotherapy who are interested in preserving ovarian function.

## CRT With Oxaliplatin Improves DFS in Locally Advanced Rectal Cancer

Written by Emma Hitt Nichols, PhD

Treatment with oxaliplatin plus 5-fluorouracil (5-FU) and radiation therapy (RT) before and after total mesorectal excision (TME) improved disease-free survival (DFS) in patients with locally advanced rectal cancer. Claus Rödel, MD, University of Frankfurt, Frankfurt, Germany, presented data from the Neoadjuvant Chemoradiotherapy and Adjuvant Chemotherapy With 5-Fluorouracil and Oxaliplatin Versus 5-Fluorouracil Alone in Rectal Cancer trial [CAO/ARO/AIO-04; NCT00349076; Rödel C et al. *J Clin Oncol* 2014].

Preoperative chemoradiotherapy (CRT) with TME and 5-FU-based adjuvant chemotherapy was established as the standard of care in patients with locally advanced rectal cancer by the CAO/ARO/AIO-94 trial [Sauer R et al. *N Engl J Med* 2004]. However, more effective therapy is needed. Previous Phase 1/2 trials demonstrated that oxaliplatin plus capecitabine and RT was a feasible, active treatment [Rödel C et al. *J Clin Oncol* 2007; Rödel C et al. *J Clin Oncol* 2003]. The purpose of this trial was to further evaluate CRT in patients with locally advanced rectal cancer.

In the Phase 3 CAO/ARO/AIO-04 trial, 1265 patients with locally advanced rectal cancer were randomly assigned to receive RT plus 5-FU and to continue 5-FU after TME (n=637) or to receive RT plus 5-FU and oxaliplatin followed by oxaliplatin, folinic acid, and 5-FU (mFOLFOX6) after TME (n=628). Patients were eligible for the trial if they had an Eastern Cooperative

Oncology Group performance status (ECOG PS) 0 to 2, and histologically proven, advanced primary carcinoma of the rectum (tumor within 12 cm from the anal verge), with clinically staged T3/4 or any node-positive disease

The primary endpoint was DFS, and the main secondary endpoints were toxicity and compliance, R0 resection rate, pathologic complete response (pCR) and tumor regression, recurrence, and overall survival (OS). The baseline characteristics of patients were similar in both arms: median age 63.5 years, 71% male, and 77.5% with an ECOG PS of 0. Adjuvant chemotherapy after TME was initiated in 77.5% of patients; common reasons to not start adjuvant chemotherapy included postoperative complications, patient refusal, and disease progression. The median time interval between CRT and TME was 42 days in both arms.

In the intention-to-treat population, the addition of oxaliplatin to 5-FU and RT resulted in a significant increase in DFS over a follow-up period of 50 months (HR, 0.79; 95% CI, 0.64–0.98; p=0.030). The 3-year DFS rates were 75.9% in the 5-FU-only arm and 71.2% in the oxaliplatin arm; the 5-year DFS rates were 68.8% in the 5-FU-only arm and 64.3% in the oxaliplatin arm. A subgroup analysis suggested that the addition of oxaliplatin benefited patients regardless of age, gender, tumor stage, or nodal disease status. However, there was no significant difference in OS between the 2 arms (HR, 0.96; 95% CI, 0.72–1.26; p=0.752).

Overall, 20% and 24% of patients who received CRT with 5-FU or CRT with 5-FU and oxaliplatin experienced grade 3/4 adverse events. Common grade 3/4 adverse events included gastrointestinal, hematologic, genitourinary, and neurologic effects.

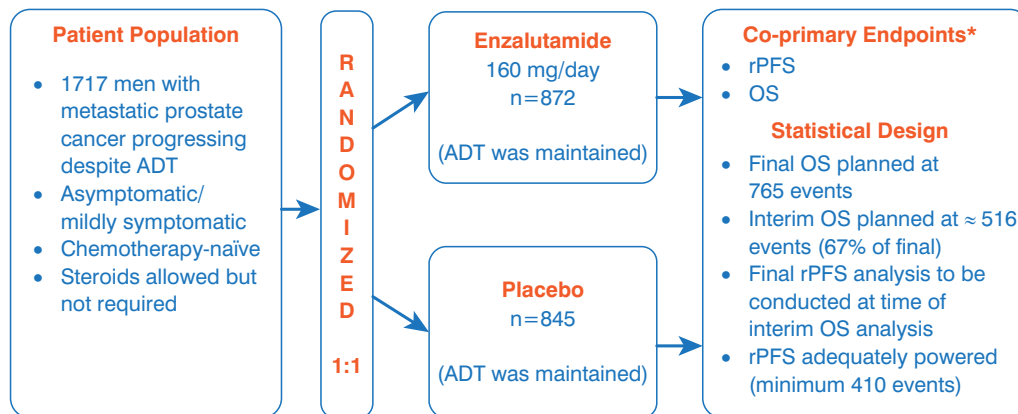
Prof. Rödel stated that the results from the CAO/ARO/AIO-04 trial suggest that the addition of oxaliplatin to 5-FU and RT before and after TME was well tolerated, increased the pCR rate, and improved DFS in patients with locally advanced rectal cancer.

## Safety and Efficacy of Enzalutamide in Men With Metastatic Prostate Cancer: The PREVAIL Trial

Written by Jill Shuman

Andrew Armstrong, MD, Duke Department of Medicine, Durham, North Carolina, USA, provided data from A Safety and Efficacy Study of Oral MDV3100 [enzalutamide] in Chemotherapy-Naïve Patients With Progressive Metastatic Prostate Cancer [PREVAIL; NCT01212991; Beer TM et al. *N Engl J Med* 2014]. Enzalutamide, an androgen

Figure 1. PREVAIL Trial Design



ADT=androgen deprivation therapy; OS=overall survival; rPFS=radiographic progression-free survival.

\*Total alpha=0.05, 2-sided (OS allocation=0.049; rPFS allocation=0.001); target hazard ratio: OS=0.82, rPFS=0.57.

Reproduced with permission from A Armstrong, MD.

receptor inhibitor, has been shown to improve overall survival (OS) and radiographic progression-free survival (rPFS) in men with metastatic castrate-resistant prostate cancer (mCRPC) who had received docetaxel therapy [Scher H et al. *N Engl J Med* 2012]. PREVAIL researchers examined whether enzalutamide could prolong OS and rPFS in men with mCRPC who had progressed on androgen deprivation therapy (ADT).

The multinational PREVAIL—a randomized, double-blind, placebo-controlled study—enrolled asymptomatic or mildly symptomatic men to enzalutamide (160 mg/day; n=872) or placebo (n=845), with respective median treatment durations of 16.6 and 4.6 months. The coprimary endpoints were OS and rPFS, and these were analyzed for the intent-to-treat population (Figure 1). Other efficacy endpoints included time to cytotoxic chemotherapy, time to neoplastic treatment, time to first skeletal-related event, time to prostate-specific antigen (PSA) progression, time to Functional Assessment of Cancer Therapy-Prostate degradation, best objective response, and PSA decline from baseline. The treatment groups were well balanced relative to baseline patient characteristics and baseline disease burden.

Enzalutamide, when compared with placebo, significantly prolonged rPFS (65% vs 14% at 12 months;  $p<0.0001$ ), reduced the risk of death by 29% ( $p<0.0001$ ), delayed the median time to chemotherapy by 17 months (HR, 0.72), and delayed time to PSA progression ( $p<0.0001$ ). With enzalutamide, there was an objective soft tissue response (complete response plus partial response) of 59%, compared with 4.9% for placebo ( $p<0.0001$ ), and a reduced time until the first skeletal-related event (HR,

0.72;  $p<0.001$ ). Furthermore, enzalutamide was beneficial over placebo for the rate of decline of  $\geq 50\%$  in PSA (78% vs 3%;  $p<0.001$ ). Dr. Armstrong also provided an updated OS analysis (Table 1).

Table 1. Updated OS Analysis as of January 15, 2014<sup>a</sup>

	Placebo (n=845)	Enzalutamide (n=872)
Median OS follow-up, months	26.5	26.2
Deaths at time of analysis, n (%)	357 (42)	299 (34)
Median duration of OS, months	31.0	Not yet reported

OS=overall survival.

<sup>a</sup>Relative to primary OS analysis: 116 additional deaths, for a total of 656 deaths; 4 months of additional OS follow-up. HR, 0.73; 95% CI, 0.63 to 0.85;  $p<0.001$ .

Given a planned interim analysis at 540 deaths, the Data Monitoring Committee recommended that the study be stopped and that patients in the placebo group cross over to the enzalutamide group. The most common adverse events with a higher incidence in the enzalutamide arm than the placebo arm were fatigue (35.6% vs 25.8%), back pain (27.0% vs 22.2%), constipation (22.2% vs 17.2%), and arthralgia (20.3% vs 16.0%). Seizure was reported in 1 patient in each treatment arm (0.1%).

In summary, for men with mCRPC who have progressed on ADT but have not received chemotherapy, treatment with enzalutamide has a favorable safety profile and significantly improves OS, rPFS, and secondary measures of disease response and progression.